

## ABDOMINAL PAIN AS THE MAIN SYMPTOM OF PERIMYOCARDITIS: A CASE REPORT

Florencia Brito<sup>a\*</sup>

Sari Haryati<sup>b</sup>

<sup>a</sup>Medical student, Facultad de Medicina Clínica Alemana de Santiago - Universidad del Desarrollo, Chile.

<sup>b</sup>Doctor graduated, Faculty of Medicine - Andalas University, Indonesia.

Received 15 April 2020, Accepted 17 July 2020.

### ABSTRACT

**Introduction:** acute myocardial inflammation with pericardial involvement may frequently occur with a clinical presentation of chest pain, pericarditis or pseudo-ischemic, sign of heart failure, palpitation, or unexplained arrhythmia. There is limited information about clinical presentation with symptoms different to those related to the cardiovascular sphere. **Objective:** the purpose of this case report is to expose a different and unknown clinical presentation of perimyocarditis. **Methodology:** the methodology of this clinical case is based on the compilation of information about the medical history of the patient and the details of the clinical presentation of the current case. Furthermore, it is based on an exhaustive follow-up of the patient's evolution during the hospitalization. All of the above was done with the consent of the patient, its family, and with the supervision of the doctor in charge of the intensive care unit of the cardiology department. **Discussion:** if the different symptoms that perimyocarditis can present are not reported, it is difficult to opportunely diagnose it. This has a great impact on health centers that are lacking of technology and basic supplies to diagnose perimyocarditis, having at their disposal only the anamnesis and physical examination to determine their diagnoses. **Conclusion:** the medical community should include epigastric pain as a possible clinical symptom of an acute myocardial inflammation with concomitant pericardial involvement in order to make better decisions, reach to the correct early diagnosis, and prompt treatment to the patient.

**Key words:** Myocarditis, Perimyocarditis, Pericarditis, Epigastric pain, Cardiogenic shock.

### INTRODUCTION

Myocarditis is an inflammatory disease of the myocardium with a wide range of clinical presentations, ranging from mild symptoms of chest pain and palpitations to life-threatening conditions, such as cardiogenic shock and ventricular arrhythmia<sup>1,2</sup>.

The incidence is undetermined due to the unfrequently use of endomyocardial biopsy (EMB), which is the diagnostic gold standard<sup>3</sup>, and also because of challenging diagnosis of this disease due to the variety of clinical presentations<sup>4</sup>.

The etiologies of the myocarditis also remain undetermined, however it can be attributed to infectious agents (bacteria, viruses, parasites), systemic disease (lupus, rheumatoid arthritis, scleroderma), immune-mediated factors (alloantigen such as heart transplant rejection and auto-antigens), drugs (antibiotics, lithium, amphetamines), and toxins (heavy metals such as copper, iron)<sup>5</sup>. The most common cause in North America and Europe is the viral infection<sup>1,6</sup>. Moreover, myocarditis can also be related with concomitant pericarditis as they share common etiologies<sup>8,9</sup>. This corresponds to perimyocarditis which implies a predominant myocardial inflammation with pericardial involvement<sup>10</sup>.

Diagnostic criteria for clinically suspected myocarditis can be described by clinical presentation (acute chest pain, pericarditis or pseudo-ischemic, new onset or chronic or worsening of dyspnea on exercise, fatigue, with or without heart failure sign,

palpitation, unexplained cardiogenic shock), and diagnostic criteria (electrocardiogram (ECG), laboratory markers, cardiac imaging abnormalities and tissue characterization by CMR)<sup>2</sup>.

As can be seen, this criterion does not include different symptoms to those related with the cardiovascular sphere. Moreover, this criterion can have limitations in social contexts with low economic resources and with no implements to do ECGs, echocardiography, cardiovascular magnetic resonance (CRM), biopsies, among others, to support or discard the suspicion of a cardiac origin of the syndrome. The purpose of this clinical case is to contribute with new knowledge about a different clinical presentation in order to make better decisions, reach to the early diagnosis, and give prompt treatment to the patient.

### CLINICAL CASE

A 58-year-old woman without previous comorbidities came to our hospital with epigastric pain since two days before admission. She described a progressive pain, localized in the epigastrium without any migration or radiation. The pain had a burning character, with no triggers, no aggravating, or attenuating. At the beginning, the pain was also accompanied by flu-like syndrome, fever, intermittent nausea, fatigue, and tensional headache. No reflux, vomiting, hematemesis, melena, neither hematochezia. No diaphoresis and no loss of body weight. There was no symptomatology like this before.

\*Correspondencia: fbritog@udd.cl  
2020, Revista Confluencia, 2(1), 110-113



During the first day, the intensity of the pain increased and she consulted to a small hospital where she was diagnosed with dyspepsia and was suggested to control on an outpatient clinic with Omeprazole therapy. Since during the second day the symptoms had gotten worse, she consulted another hospital where she arrived with a several hemodynamic compromise. She was diagnosed with acute myocardial infarction, cardiogenic shock, and a suspicion of diathesis hemorrhagic. She received Norepinephrine, Atorvastatin, and Ranitidine. She did not receive any antiplatelet aggregator because of suspicion of diathesis hemorrhagic.

Afterwards, she was derived to our hospital on January 7th, 2019 at 20:55 with epigastric pain and atypical chest pain. The patient did not present antecedents of chest pain, palpitations, orthopnea, nocturnal paroxysmal dyspnea, edema, nocturia, neither dyspnoea of efforts before. About the cardiovascular risk factors, >65 years old (-), menopause (+), arterial hypertension (-), type 2 diabetes (-), smoker (-), familiar cardiovascular antecedents (-) and dyslipidemia unknown.

In the physical examination, the patient presented moderate general appearance and no alteration of consciousness, hypotension (88/65 mmHg), tachycardia (126 pulses per minute), and tachypnea (24 cycles per minute). Temperature of 36.6°C (axillary), and neck pressure of 5+0 mmHg. Head and neck were normal with pink-color and hydrated mucosa and submucosa, without palpable thyroid and no presence of lymphadenopathy. Lungs without rhonchi or wheezing. Heart was normal with regular heartbeat, no murmur, no gallop neither pericardial friction rubs. The abdomen was soft and depressible, sensitive to deep palpation on the epigastrium. Liver and spleen were not palpable. No ascites. Finally, lower extremities were cold on palpation, without edema.

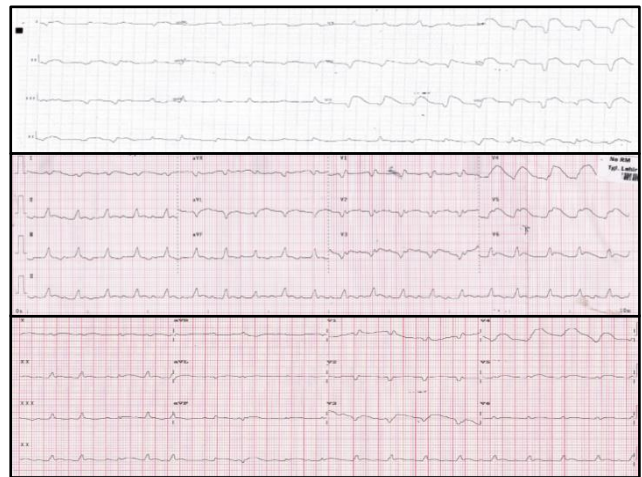
Two ECG were taken; one in the emergency room (ER) when the patient arrived and the second one an hour after in our Cardiovascular Care Unit (CVCU). The first ECG taken was also available. These are present on Figure 1. All of them show sinus tachycardia and a convexly elevated J-ST segment in almost every derivate.

A chest x-ray was taken one hour after admission and it showed cardiomegaly, a thickening of pericardium and perihilar vasculature. As the pulmonary physical examination was normal and the patient did not exhibited shortness of breath, cough or expectoration, it was not diagnosed with pneumonia. Nonetheless, it received Ceftriaxone as prevention.

On laboratory were found hemoglobin level of 12.1 gr/dL, hematocrit of 37%, leukocyte of 15.110/mm<sup>3</sup>, platelet of 175.000/mm<sup>3</sup>. Sodium level was at 128 mEq/dl, potassium of 4.2 mEq/dl, calcium of 8.4 mEq/dl and chloride of 96 mEq/dl. Random glucose test at 138 mg/dl with urea 71 mEq/dl and creatinine

0.9 mg/dl. The troponin I at > 40.000 ng/L and CRP was positive.

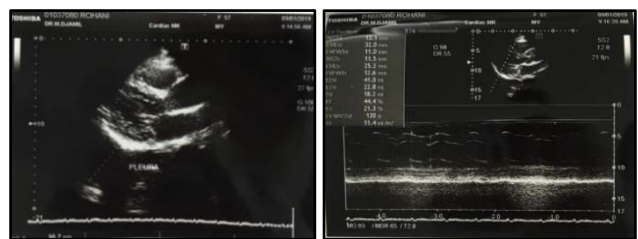
Patient was assessed as suspicious perimyocarditis. In ER the patient had oxygenation with 4 lpm binasal cannula, IVFD NaCl 0.9% 500cc/24 hours, Norepinephrine drip, Aspirin 3 x 750 mg, Ranitidine 2 x 50 mg. The patient was planned to be taken to the CVCU.



**Figure 1.** On the top: First ECG at the first healthcare center that the patient consulted. In the middle: Second ECG at Emergency Room of our Hospital, one and a half hour after the first ECG. And beneath: Third ECG at Cardiovascular Care Unit (CVCU), one hour after the second ECG.

It was proceed with a coronary angiography and the results showed: Left marginal artery (LMA) normal, left anterior descending (LAD) normal, left circumflex artery (LCX) irregular vessel in proximal, right coronary artery (RCA) normal and right dominance. Since there was no obstruction, it allowed us to rule the hypothesis of acute coronary syndrome out. The main diagnosis at that moment was an acute myocarditis with a possible concomitant pericardial involvement, which could have explained the cardiogenic shock.

A transthoracic echocardiography was carried out due to the recommendation of the management of acute myocarditis<sup>11</sup>. The results are in the Figure 2.



**Figure 2.** Transthoracic Echocardiogram at CVCU

The echocardiography showed a decrease of ejection fraction 44% with regional wall motion abnormalities and minimal pericardial effusion in lateral and posterior right ventricle (RV).

At this point, it fulfilled criteria of clinically suspected myocarditis<sup>2</sup>. There was one of the possible clinical presentations (unexplained cardiogenic shock) and three of the four diagnostic criteria (ECG outcomes, elevated Troponin I (TnI) and echo abnormalities). In addition, there was no coronary artery disease proved by angiography and either a known pre-existing cardiovascular disease or extra-cardiac causes that could explain the syndrome. The involvement of pericarditis was confirmed due to the pericardial effusion and the elevation of the ST segment in the ECGs, these corresponded to two of four criteria to diagnose pericarditis regarding to ESC guideline<sup>12,13</sup>. Therefore this patient was diagnosed with perimyocarditis.

Owing to the limited resources of the hospital, the etiological study of the myocarditis was not effectuated since the hospital did not count with the possibility of carrying out an endomyocardial biopsy or a Cardiac Magnetic Resonance (CMR). As in the literature it is recommended<sup>13</sup>.

For that reason, the patient was hospitalized, monitored, and treated with the actual literature recommendation; Aspirin 750 mg every 8 hours for two weeks or Ibuprofen 600 mg every 8 hours for two weeks, Colchicine 0.5mg once per day for three months and exercise restriction for 4 to 6 weeks<sup>2,12</sup>.

Unfortunately, three days after the patient was taken, it developed bacterial pneumonia and concomitant urinary tract infection. These were treated with 2 grams of Ceftriaxone once a day and Azithromycin 500mg once a day. Despite having completed 6 days of the treatment, the patient developed sepsis with a rapid onset of disseminated intravascular coagulation (DIC), a severe hyponatremia and delirium. Even though all the medical efforts, the patient died within a few hours.

## DISCUSSION

There are only few investigations about perimyocarditis with different clinical presentations of specifically cardiac symptoms<sup>14,15</sup>. Even more, there is no information about the relation between epigastric pain and perimyocarditis.

Diagnostic criteria for clinically suspected myocarditis can be described by clinical presentation (acute chest pain, pericarditis or pseudo-ischemic, new onset or chronic or worsening of dyspnea on exercise, fatigue, with or without heart failure sign, palpitation, unexplained cardiogenic shock) and diagnostic criteria (ECG, laboratory markers, cardiac imaging abnormalities and tissue characterization by CMR). With one or more clinical presentations added to one or more of the four diagnostic criteria and also in absence of (1)coronary artery disease proved by angiography (2) known pre-existing cardiovascular disease or extra-cardiac causes that could explain the syndrome (e.g. valve disease, congenital heart disease, hypothyroidisms, or others) it is possible to

clinically suspect myocarditis<sup>2</sup>. The higher the number of fulfilled criteria, the higher is the suspicion. And in cases of asymptomatic patients it is necessary to present two or more of the four diagnostic criteria.

Moreover, this criteria could not be useful in social contexts with low economic resources and with no implements to do ECGs, echocardiography, CRM, biopsies, among others, to support or discard the suspicion of a cardiac origin of the syndrome.

In this case, when the patient consulted for the first time none of the criteria describes above was fulfilled, due to the fact that epigastric pain is not included as a possible clinical presentation of myocarditis, nevertheless the epigastric pain was misdiagnosed as dyspepsia. This misdiagnosis is one of the limitations that can be recognized in this clinical case.

Firstly, if there had been more knowledge about the relationship between epigastric pain and acute cardiac syndromes, then better decisions could have been made, the correct diagnosis could have been reached faster, and the patient could have received the appropriate treatment and cares on time.

Secondly, in order to study the etiology of the perimyocarditis it was necessary to carry out an endomyocardial biopsy or a Cardiac Magnetic Resonance as is recommended in the literature<sup>13</sup>. Nonetheless, these were not performed due to the limited recourses of the hospital. For that reason the specific treatment to deal with the cause of the myocarditis could not be given.

Finally, the treatment for the perimyocarditis was not completed because of the critical health condition of the patient after the nosocomial infections. If the treatment had been completed, it would be expected a normalization of the ECG, an improvement of the left ventricular function, and a recovery of the exercise capacity within 12 months as is reported in the actual literature<sup>8</sup>.

This case reminded us about the importance of making good anamnesis and accusative physical examination in order to achieve accurate diagnosis. For that reason, it is important to generate new documented information based on the experiences like this case report, in order to inform about the different signs and symptoms, above the ones that we already know of perimyocardial diseases, and therefore contribute to the medical community with knowledge to improve our practice and patient care.

Without any doubt, carrying out this work contributed to my training as a medical undergraduate student by helping me develop investigation skills, awakening my critical thinking skills and by showing me the importance of generating new knowledge.

## CONCLUSION

The purpose of this clinical case is to contribute with new information and knowledge about a different clinical presentation of perimyocarditis in order to make better decisions, reach to an early diagnosis,



and give prompt treatment to the patient.

The medical community should include epigastric pain as a possible clinical symptom of an acute myocardial inflammation with concomitant pericardial involvement.

## REFERENCES

- Richardson P, McKenna W, Bristow M, Maisch B, Mautner B, O'Connell J, et al. Report of the 1995 World Health Organization/International Society and Federation of Cardiology Task Force on the Definition and Classification of cardiomyopathies. *Circulation* [Internet]. 1996 [cited 2019 Jan];93:841-2 Available from: <https://doi.org/10.1161/01.CIR.93.5.841>
- Caforio A, Pankuweit S, Arbustini E, Basso C, Gimeno-Blanes J, Felix S, et al. Current state of knowledge on aetiology, diagnosis, management, and therapy of myocarditis: a position statement of the European Society of Cardiology Working Group on Myocardial and Pericardial Diseases. *Eur Heart J*. [Internet]. 2013 [cited 2019 Jan];34(33):2636-48. Available from: <https://doi.org/10.1093/eurheartj/ehd210>
- Leone O, Veinot JP, Angelini A, Baandrup UT, Basso C, Berry G, Bruneval P, et al. 2011 Consensus statement on endomyocardial biopsy from the Association for European Cardiovascular Pathology and the Society for Cardiovascular Pathology. *Cardiovasc Pathol* [Internet]. 2012 [cited 2019 Jan];21:245-74 Available from: <https://doi.org/10.1016/j.carpath.2011.10.001>
- Kindermann I, Barth C, Mahfoud F, Ukena C, Lenski M, Yilmaz A, et al. Update on myocarditis *J Am Coll Cardiol*. [Internet]. 2012 [cited 2019 Jan];59:779-2. Available from: <https://doi.org/10.1016/j.jacc.2011.09.074>
- Caforio AL, Calabrese F, Angelini A, Tona F, Vinci A, Bottaro S, Ramondo A, et al. A prospective study of biopsy-proven myocarditis: prognostic relevance of clinical and aetiopathogenetic features at diagnosis *Eur Heart J*. [Internet]. 2007 [cited 2019 Jan];28:1326-33. Available from: <https://doi.org/10.1093/eurheartj/ehm076>
- Kühl U, Pauschinger M, Noutsias M, Seeborg B, Bock T, Lassner D, et al. High prevalence of viral genomes and multiple viral infections in the myocardium of adults with 'Idiopathic' left ventricular dysfunction *Circulation* [Internet]. 2005 [cited 2019 Jan];111:887-93. Available from: <https://doi.org/10.1161/01.CIR.0000155616.07901.35>
- Dennert R, Crijns HJ, Heymans S. Acute viral myocarditis *Eur Heart J*. [Internet]. 2008 [cited 2019 Jan];29:2073-82. Available from: <https://doi.org/10.1093/eurheartj/ehn296>
- Imazio M, Cecchi E, Demichelis B, Chinaglia A, Ierna S, Demarie D, et al. Myopericarditis versus viral or idiopathic acute pericarditis *Heart* [Internet]. 2008 [cited 2019 Jan];94:498-501. doi:10.1136/hrt.2006.104067
- Imazio M, Brucato A, Barbieri A, Ferroni F, Maestroni S, Ligabue G, et al. Good prognosis for pericarditis with and without myocardial involvement: results from a multicenter, prospective cohort study. *Circulation* [Internet]. 2013 [cited 2019 Jan];128:42-9. Available from: <https://doi.org/10.1161/CIRCULATIONAHA.113.001531>
- Imazio M, Trincherò R. The spectrum of inflammatory myopericardial diseases. *Int J Cardiol* [Internet]. 2010 [cited 2019 Jan];144(1):134. Available from: doi:10.1016/j.ijcard.2008.12.118.
- Felker GM, Boehmer JP, Hruban RH, Hutchins GM, Kasper EK, Baughman KL, et al. Echocardiographic findings in fulminant and acute myocarditis. *J Am Coll Cardiol*. 2000 Jul;36:227-32.
- Adler Y, Charron P, Imazio M, Badano L, Barón-Esquivias G, Bogaert J, et al. 2015 ESC Guidelines for the diagnosis and management of pericardial diseases: The Task Force for the Diagnosis and Management of Pericardial Diseases of the European Society of Cardiology (ESC) *Eur Heart J*. [Internet]. 2015 [cited 2019 Jan];36(42):2921-64. Available from: <https://doi.org/10.1093/eurheartj/ehv318>.
- Imazio M, Trincherò R. Myopericarditis: etiology, management, and prognosis *Int J Cardiol* [Internet]. 2008 [cited 2019 Jan];127(1):17-26. Available from: doi:10.1016/j.ijcard.2007.10.053.
- Lamback EB, Morandi G, Rapti E, Christov G, Brogan PA, Hindmarsh P. Addison's disease presenting with perimyocarditis *J Pediatr Endocrinol Metab* [Internet]. 2018 [cited 2019 Jan];31(1):101-5. doi: 10.1515/jpem-2017-0278.
- Plenzig S, Heinbuch S, Held H, Verhoff MA, Lux C. A case of fatal perimyocarditis due to a rare disease. *Forensic Sci Med Pathol*. 2017 Dec;13(4):454-8. doi: 10.1007/s12024-017-9920-3. Epub 2017 Oct 11

